

SMOOTHLIPO™ TECHNIQUE FOR MINIMALLY INVASIVE SKIN TIGHTENING AND RETRACTION

Michail M. Pankratov¹, Serge Mordon,² Jean-Luc Cohen³

¹Elemè Medical, Inc., Merrimack, NH

²INSERM U 703, Lille University Hospital, Lille France

³Marseille, France

Background and Objective:

Laser lipolysis became an adjunct to liposuction procedures primarily for its ability to produce near instantaneous tissue tightening.

Secondarily, for the stimulation of collagen and elastin production which contributes to sustained tissue tightening.

Debate continues as to which laser wavelength is better suited for delivery of these benefits.

Three years of clinical experience with Osyris Pharaon 980 nm laser generated a body of knowledge for its safe and efficacious use.

The purpose of this study was to determine if laser lipolysis, specifically the use of 980nm wavelength, would improve the surgical outcome by producing tissue tightening and skin retraction, with a higher margin of patient safety.

Study Design and Methods:

SmoothLipo™ technique utilizes a continuous wave 25 W 980 nm diode laser. Its energy is delivered subcutaneously via a cannula containing a 600 µm quartz fiber.

Twelve patients with various amounts of subcutaneous fat and skin laxity on the neck, upper arms, abdomen, flanks, saddlebags, thighs, etc. were injected with tumescent anesthesia and treated for these conditions with a laser-lipolysis technique followed by a traditional liposuction. The end-point of laser-lipolysis treatment was an external skin temperature of $38 \pm 2^\circ \text{C}$ as monitored by remote thermography.

The power settings and total energy delivered depended on the body area and the volume of subcutaneous fat. The lowest power of 6-10 W (total energy up to 5 kJ) on the neck and highest power of 20-25 W (energy up to 25 kJ) on the abdomen; other body areas were treated at intermediate settings.

Results:

Early results demonstrate substantial benefit to the patients in terms of nearly instantaneous tissue tightening and skin retraction as assessed by the surgeon and patient. While these results are remarkable immediate post surgery, there is a continuous improvement over time. Most striking improvements were observed in submental area, lower abdomen and upper arms. The side effects were limited to those associated with traditional liposuction.

Conclusion:

Addition of laser-lipolysis to the armament of liposuction delivers minimally invasive tissue tightening and skin retraction, improves surgical outcome and expands population of patients that can benefit from the procedure without additional surgery.

Background and Objectives

Laser lipolysis became an adjunct to liposuction procedures primarily for its ability to produce near instantaneous tissue tightening. Secondly, for the stimulation of collagen and elastin production which contributes to sustained tissue tightening. Laser lipolysis

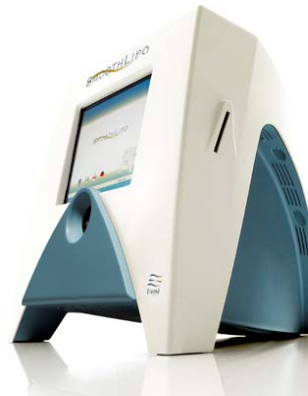Laser lipolysis is especially suited for small areas of localized fat deposits especially in those areas where skin laxity may be worsened by traditional liposuction. In addition laser lipolysis can be used for skin tightening alone.

Debate continues as to which laser wavelength is better suited for delivery of these benefits. Three years of clinical experience with Osyris Pharaon 980 nm laser generated a body of knowledge for its safe and efficacious use.

SmoothLipo laser lipolysis device utilizes 980nm continuous wave laser energy to produce photothermal adipocyte apoptosis. 980nm light has three times better water absorption than 1064nm light and 3 times better depth of penetration than 1320nm.

The purpose of this study was to determine if laser lipolysis, specifically the use of 980nm wavelength, would improve the surgical outcome by producing tissue tightening and skin retraction, with a high margin of patient safety.

Continuous wave 980 nm wavelength provides a faster, more homogenous heating of the targeted area providing a more uniform result. It also allows higher energies to be used more safely.



Study Design and Methods

A study of twelve female patients between the ages of 18 and 65 was conducted to evaluate the safety and efficacy of the SmoothLipo™ technique which utilizes a continuous wave 25W 980 nm diode laser. Each patient presented with various degrees of subcutaneous fat and skin laxity ranging from mild to severe. Treatment areas included neck, upper arms, abdomen, flanks, lateral and medial thighs.

Prior to the SmoothLipo procedure, all patients underwent standard liposuction pre-operative screening, teaching and consents. In addition, photographic imaging of the treatment area was obtained.

The selected treatment area was injected with tumescent anesthesia followed by the introduction of a 16G sterile, stainless steel cannula containing a 600-µm fiber (Figure 1). The treatment area was divided into segments based on the size of the area. The deeper fat layer was treated first by moving the laser fiber back and forth in a fanning pattern. The deep layer was treated until the desired resistance was achieved. Next, the superficial layer was treated. At which point external skin temperatures were recorded. The end-point of laser lipolysis treatment was an external skin temperature of $38 \pm 2^\circ\text{C}$ as monitored by remote thermography. Thermal imaging (Figure 2) was also obtained using infrared video imaging.

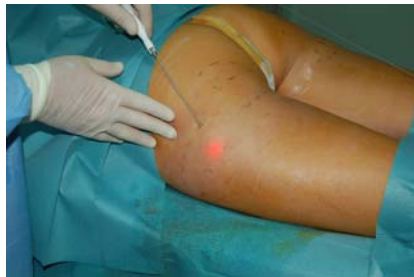

Figure 1

Treatment parameters varied based on the area being treated. Power setting and total energy delivered depended on the body area and volume of subcutaneous fat. The lowest power of 6-10W (total energy up to 5 kJ) on the neck and highest power of 20-25W (energy up to 25kJ) on the abdomen were administered. Other body areas were treated at intermediate settings.

After the use of laser-lipolysis, larger areas underwent traditional liposuction. Manual expression of fat and tumescence occurred in all treatment areas. Insertion sites were left open for drainage.

Post procedure care consisted of wearing compression garment for 20 days post procedure. Healthy diet and physical activity were encouraged after the procedure.

Patients returned up to 6 months post procedure for evaluation.




Figure 2: Thermal imaging using infrared video. The image on the left shows the submental area at approximately 35 °C. The image on the right shows the area immediate post tx at approximately 40 °C.

Results and Conclusion

Results:

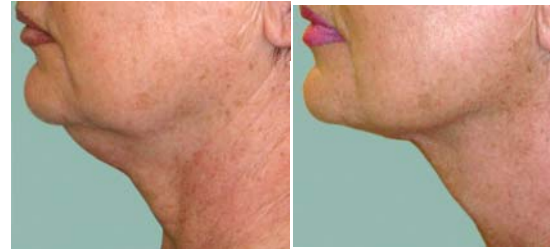All twelve patients demonstrated moderate to significant improvement in skin laxity as well as subcutaneous fat reduction immediate post procedure, with continued improvement for up to 6 months.

Immediate side effects were minimal edema and mild bruising with no incidence of burns or infection.

Subjects were able to resume normal daily activities on an average of 2 days post procedure.

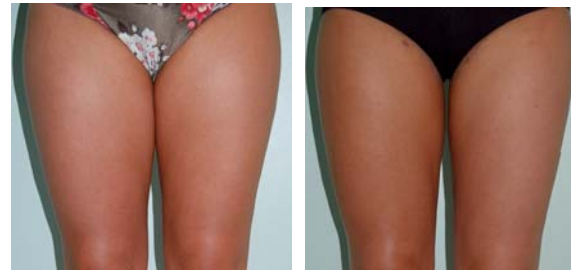Conclusion:

Addition of laser-lipolysis to the armament of liposuction delivers minimally invasive tissue tightening and skin retraction, improves surgical outcome and expands population of patients that can benefit from the procedure without additional surgery.



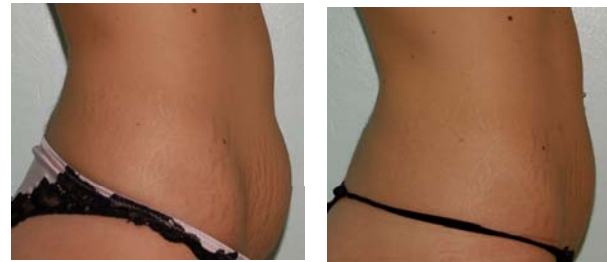
Submental Pre Submental 5 Month

Photos Courtesy of Dr. Jean-Luc Cohen



Medial Thighs Pre Medial Thighs 5 Month

Photos Courtesy of Dr. Jean-Luc Cohen



Abdomen Pre Abdomen 5 Month

Photos Courtesy of Dr. Jean-Luc Cohen